ORIGINAL RESEARCH ARTICLE

Histopathological Study Of Neoplastic And Non- Neoplastic Skin Lesions In A Tertiary Care Hospital

Arthy Subramanian[1]*, Peravali Nalini[2], Arun Kumar Jacob[3], Lionel Mathew[4], Saraswathi Manikam[5], Radha Raja Prabha[6]

[1]Assistant Professor of the Department of Pathology, Sri Muthukumaran Medical College and Research Institute, India
[2]Assistant Professor of the Department of Pathology, Sri Muthukumaran Medical College and Research Institute, India
[3]Assistant Professor of the Department of Dermatology, Sri Muthukumaran Medical College and Research Institute, India
[4]Associate Professor of the Department of Pathology, Sri Muthukumaran Medical college and research institute, India
[5]Professor of the Department of Pathology, Sri Muthukumaran Medical College and Research Institute, India
[6]Professor of the Department of Dermatology, Sri Muthukumaran Medical College and Research Institute, India

Corresponding Author: Arthy Subramanian
Email: osarthy@gmail.com

Abstract: Introduction: Skin lesions are a group of disorders ranging from inflammation, infections, cysts, vascular problems, benign tumors, to malignancies. While many of the skin diseases can be diagnosed based on their clinical picture, histopathology is an integral part of the diagnosis in complex cases. Clinicopathological correlation is necessary to increase diagnostic accuracy and determine the treatment modalities.**Objective:** To evaluate the histopathological spectrum of benign and malignant skin lesions in a tertiary care hospital and to compare the clinical and histopathological diagnoses.**Materials and methods:** This was a retrospective, hospital-based observational study conducted in the Department of Pathology of a tertiary care teaching hospital. All the histopathology registers, along with the respective pathology reports of the skin biopsies/excision done in the study period, were analyzed. Relevant demographic, anatomical, clinical, and histopathological information was collected from the medical records. The specimens underwent routine fixation, processing, paraffin embedding, and sectioning, followed by staining with Hematoxylin and Eosin (H&E). Special stains were done in a few cases to diagnose the condition.**Results:** A total of 275 skin biopsy specimens were analysed. The most common were cystic lesions, which had a total of 135 (49.1%) cases, while 120 (88.9%) were epidermal cysts. There were 27 (9.8%) microbial diseases, 23 (8.4%) benign neoplastic lesions, 18 (6.5%) hyperkeratotic/reactive keratotic lesions, and 11 (4.0%) malignant neoplasms. There was a total of 207 (75.3%) with complete pathological concordance, 19 (6.9%) had partial concordance, while there were 49 (17.8%) with complete discordance.**Conclusion:** This study shows the different histopathological profile of skin lesions, wherein the cystic lesions are the most common. Histopathology has great diagnostic significance; nonetheless, the number of discordant cases reveals the significance of proper clinical information, correct biopsy, and clinicopathological correlation.

Keywords: Adnexal neoplasms, Cystic lesions, Dermatopathology, Papulosquamous diseases, Skin biopsy

Received:28.09.2026 | Revised:20.10.2026 | Accepted:06.11.2026 | Published:21.11.2026

Citation: Arthy Subramanian *et al* (2026). Histopathological study of neoplastic and non- neoplastic skin lesions in a tertiary care hospital. STEMed, 7(2): 144-156.

INTRODUCTION

Skin is the largest organ in the body and constitutes a considerable portion of the integumentary system. It includes epidermis, dermis, subcutis, skin appendages, and melanocytic system. It has many functions such as protection against external environment, regulation of body temperature, regulation of body fluid, and sensory perception. The skin, owing to its increased exposure to the environment, infectious agents, and occupational risks, is afflicted by a variety of disorders that may be inflammatory, infectious, or benign/malignant

 © 2026 Arthy Subramanian et al. Open Access under the Creative Commons Attribution 4.0 International License.

tumors [1–3].

Skin diseases constitute one of the most frequent health problems of people across the globe and particularly in developing countries. Their occurrence varies widely across geographic regions based on many determinants including age, sex, climatic conditions, economic status, education, occupation, ethnic background, genetics, nutritional status, environmental exposure, and sociocultural practices [3]. The incidence of skin diseases in India is reported to range from 6.3% to 11.6% [3,4], wherein infective and non-infective types of skin diseases have been major contributors towards this disease burden.

In terms of clinical appearance, skin lesions usually appear with only a few types of morphological appearance, such as macules, papules, plaques, nodules, vesicles, ulcers, and pigmentary changes. Some conditions having totally different etiology, treatment, and prognosis may present with identical clinical appearance. Although most of the dermatological disorders can be correctly diagnosed clinically by doing a proper history and physical examination, there are cases where further tests may be necessary for the correct diagnosis. The histopathological examination of the skin biopsy remains one of the diagnostic tools in dermatology, especially if there is any doubt about the clinical diagnosis and differentiation between inflammatory, infective, benign and malignant skin lesions is required [5–7].

Histopathological examination shows changes in the architecture and cells of the epidermis, dermis and subcutaneous tissues. There are different biopsy procedures that may be done based on the type and location of the lesion such as punch biopsy, shave biopsy, incisional biopsy and excisional biopsy. The punch biopsy is one of the common biopsy techniques used in dermatology because it is easy, quick, and gives enough full thickness tissue sample. Other staining procedures may also be done for identifying the infectious agents [8].

While skin diseases have a significant burden, there is a large variation in the spectrum of histopathological appearances of skin lesions across different geographical regions and health-care facilities. It is thus important to conduct local studies to find out the distribution of lesions and patterns, which might be different from other regions. In addition, a comparison of clinicopathological correlation can help in determining diagnostic scenarios where more clinical information or a biopsy is needed.[9]

The histopathology spectrum of skin lesions is divided into inflammatory dermatosis, infective dermatosis, pigmentation abnormalities, cysts and adnexal lesions, benign neoplasms, and malignant lesions. Neoplastic lesions have particular clinical importance since early diagnosis and proper categorization of the neoplasm can help in the appropriate treatment of the lesion. Similarly, non-neoplastic lesions require early detection since their management procedures are quite different despite being clinically similar. In this case, the clinicopathological spectrum is required for diagnosis. Nevertheless, dermatological diseases are quite common; however, their histopathology is not the same in all regions. Therefore, an institution-based study will be helpful to provide us with information about the incidence and distribution of these lesions according to the age, gender, and location of the lesion. The current study was conducted to find out the histopathology and distribution of the neoplastic and non-neoplastic skin lesions.

METHODOLOGY

Study Design and Setting

It was a retrospective, hospital-based observational study done in the Department of Pathology, Sri Muthukumaran Medical College and Research Institute (SMMCH), Chennai, Tamil Nadu, India. The study was carried out to determine the spectrum and distribution of neoplastic and non-neoplastic skin lesions identified in the study period. Histopathology registers and associated pathology reports of skin biopsy and excision specimens sent to the histopathology department were reviewed retrospectively.

Study Period and Population

The study was performed over a period of five years, from January 2020 to December 2024. The study population consisted of patients who attended the departments of Dermatology, General Surgery, and ENT at SMMCH, and their skin biopsy and excision specimens sent to the Department of Pathology for histopathology evaluation.

The study included patients of all age groups and both genders irrespective of the clinical or provisional diagnosis. A total of 275 cases of skin biopsies and excisions, satisfying the inclusion criteria, were taken up. A consecutive sampling technique was employed, where all the eligible specimens during the study period were included.

Inclusion and Exclusion Criteria

Every skin biopsy or excision specimen received during the study period was eligible for inclusion without regard to the patient's age, gender, anatomic location, or clinical presentation, on condition that the specimen had adequate and well-preserved material for a clear histopathological

 © 2026 Arthy Subramanian et al. Open Access under the Creative Commons Attribution 4.0 International License.

diagnosis.

A specimen was excluded if it was inadequate, insufficient, poorly preserved, or autolyzed, or if a definitive histopathological diagnosis could not be made. A specimen was also excluded if it was a duplicate or repeat specimen from the same diagnostic encounter.

Data Collection and Histopathological Examination

The relevant demographic and clinical-pathological data were gathered retrospectively through histopathological registers, pathology reports, and clinical data where possible. Age, gender, site, nature of specimen, clinical/provisional diagnosis, and the final histopathological diagnosis were among the parameters considered. Unique study numbers were assigned to all cases, and personal identifiers were not included in the analysis.

All samples were fixed in 10% neutral buffered formalin and routinely processed through standard histopathological procedures and embedded in paraffin blocks. Sections of 3-5 µm thickness were prepared through the use of a microtome and stained with haematoxylin & eosin (H&E). The sections were studied under the light microscope, and the final diagnosis was arrived at through the characteristic histomorphological features observed.

Special stains were performed where necessary, especially for suspected infections and granulomas. Immunohistochemistry and other ancillary investigations were selectively performed when required for definitive diagnosis or further classification.

Classification and Statistical Analysis

Based on the histopathological diagnosis, the specimens were grouped into neoplastic and non-neoplastic lesions. The non-neoplastic lesions were grouped into cystic lesions, infectious or microbial lesions, inflammatory lesions, reactive and hyperkeratotic lesions, vascular lesions, vesicobullous or vesicopustular lesions, pigmentary lesions, connective tissue and metabolic lesions, degenerative and perforating lesions, and other non-neoplastic lesions. The neoplastic lesions were categorized into benign and malignant lesions, with separate categorization for adnexal neoplasms where applicable. The clinical histopathological correlation was done as complete concordance, partial concordance, discordance. Complete concordance taken the clinical data matches the final impression on histopathological examination. The partial concordance, when the clinical diagnosis does not match the histopathological examination, but a closely related condition was diagnosed clinically. Discordance is when the clinical diagnosis was not related to impression. Data were captured using Microsoft Excel, and the analysis was performed using the appropriate descriptive measures (mean and percentage).

ETHICAL CONSIDERATIONS

Institutional Ethics Committee approval was sought prior to the conduct of this study. Since this was a retrospective study based on records where there was no direct involvement of any patient in the study, a waiver of consent was obtained whenever necessary. Patient privacy was ensured at all times, and no identifiable information was included in the study database.

RESULTS

A total of 275 skin biopsy specimens were evaluated histopathologically. The study population comprised 134 males and 141 females, with a slight female predominance. The age distribution showed that the largest proportion of cases occurred among individuals aged 21–30 years, followed by those aged 31–40 years. Among males, the highest number of cases was observed in the 21–30-year age group (34 cases), whereas among females, the 31–40-year age group predominated (37 cases). The youngest age group (<10 years) included six cases, while 17 cases were aged >70 years.

Regarding anatomical distribution, the lower extremities were the most frequently involved site (60 cases), followed by the back (45 cases), upper extremities (39 cases), and face (35 cases). The scalp accounted for 25 cases, chest for 18, gluteal region for 14, neck and ear for 11 cases each, genital region for 10 cases, and abdomen for seven cases.

Spectrum of histopathological diagnoses

The histopathological spectrum demonstrated considerable diversity. Cystic lesions were the predominant category, accounting for 135 cases (49.1%), followed by microbial diseases in 27 cases (9.8%) and benign neoplastic lesions in 23 cases (8.4%). Hyperkeratotic/reactive keratotic lesions accounted for 18 cases (6.5%), while non-infectious erythematous, papular, squamous and inflammatory diseases constituted 13 cases (4.7%). Malignant neoplastic lesions were identified in 11 cases (4.0%), while adnexal neoplasms accounted for nine cases (3.3%). Vascular diseases, non-infectious vesicobullous and vesicopustular diseases, pigmentary disorders, and inconclusive specimens each accounted for six cases (2.2%). Disorders of the superficial cutaneous reactive unit constituted five cases (1.8%), other non-neoplastic lesions four cases (1.5%), connective tissue/metabolic diseases three cases (1.1%), cutaneous toxicity two cases (0.7%), and

 © 2026 Arthy Subramanian et al. Open Access under the Creative Commons Attribution 4.0 International License.

degenerative/perforating disorders one case (0.4%).

Among the 135 cystic lesions, epidermal cysts were overwhelmingly predominant, comprising 120 cases (88.9%). Dermoid cysts accounted for eight cases (5.9%), while pilar cysts constituted seven cases (5.2%). Among the 23 benign neoplastic lesions, pyogenic granuloma was the most frequent diagnosis (14 cases). Xanthomatous dermatofibroma accounted for three cases, while dermatofibroma and cornu cutaneum accounted for two cases each. Acanthotic seborrhoeic keratosis and verrucous hemangioma were identified in one case each Of the 11 malignant neoplastic lesions, basal cell carcinoma was the most common (5 cases), followed by verrucous carcinoma (3 cases) and squamous cell carcinoma (2 cases). One case of lymphoma cutis was also identified. Among the nine adnexal neoplasms, pilomatricoma was the most common diagnosis (3 cases). Nevus sebaceous was identified in two cases, while chondroid syringoma, benign adnexal neoplasm, nodular hidradenoma, and angiokeratoma accounted for one case each.

Microbial diseases accounted for 27 cases (9.8%). Of these, leprosy constituted the largest subgroup with nine cases, including tuberculoid, borderline and lepromatous spectrum lesions, as well as one case each of erythema nodosum leprosum and a lesion reported as possible early leprosy. Other bacterial diseases accounted for three cases, comprising lupus vulgaris, cutaneous tuberculosis granuloma, and tuberculosis verrucosa cutis.

Viral diseases accounted for six cases, including verruca vulgaris, infected plantar wart, myrmecia wart, and infected verruca plantaris. Other microbial lesions comprised nine cases, predominantly pilonidal sinus (seven cases), with one case each of actinomycetoma and furuncle.

Among the 14 non-infectious erythematous, papular, squamous and inflammatory lesions, psoriasis vulgaris and parapsoriasis was the most frequent diagnosis (three cases), followed by Pustular psoriasis, guttate psoriasis, pityriasis lichenoides chronica, discoid lupus erythematosus, keratosis pilaris, lichen planus pigmentosus, lichen planus, and hypertrophic lichen planus accounted for one case each.

Among vascular lesions, leukocytoclastic vasculitis predominated with four cases, while drug-induced vasculitis and neutrophilic small-vessel vasculitis accounted for one case each. The six vesicobullous/vesicopustular lesions comprised three cases of bullous pemphigoid and one case each of pemphigus vulgaris, bullous impetigo, and lichen simplex chronicus.

Comparison between the clinical diagnosis and histopathological diagnosis demonstrated complete concordance in 207 cases (75.3%). Partial concordance was observed in 19 cases (6.9%), while 49 cases (17.8%) showed discordance between the clinical and histopathological diagnoses. Thus, histopathological examination provided diagnostic confirmation or additional diagnostic information in a substantial proportion of cases where the clinical impression was not completely concordant.

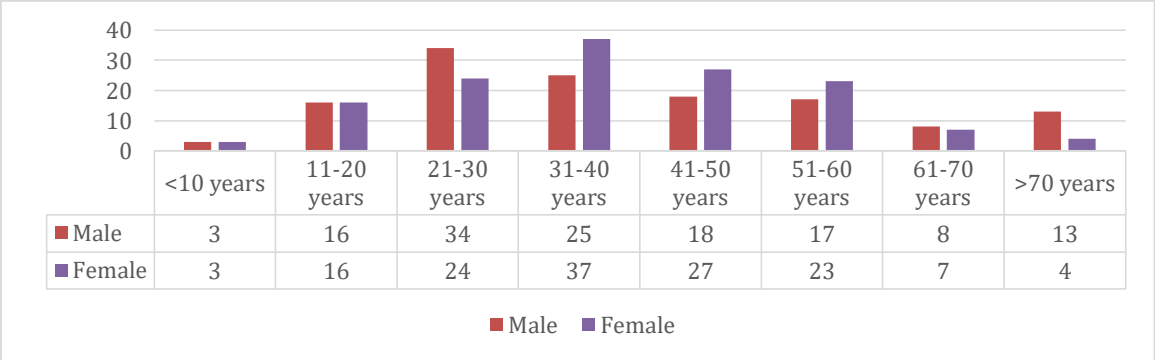

Figure 1: Age -wise Distribution of Skin Biopsy Specimens Included in the Study (n = 275)

 © 2026 Arthy Subramanian et al. Open Access under the Creative Commons Attribution 4.0 International License.

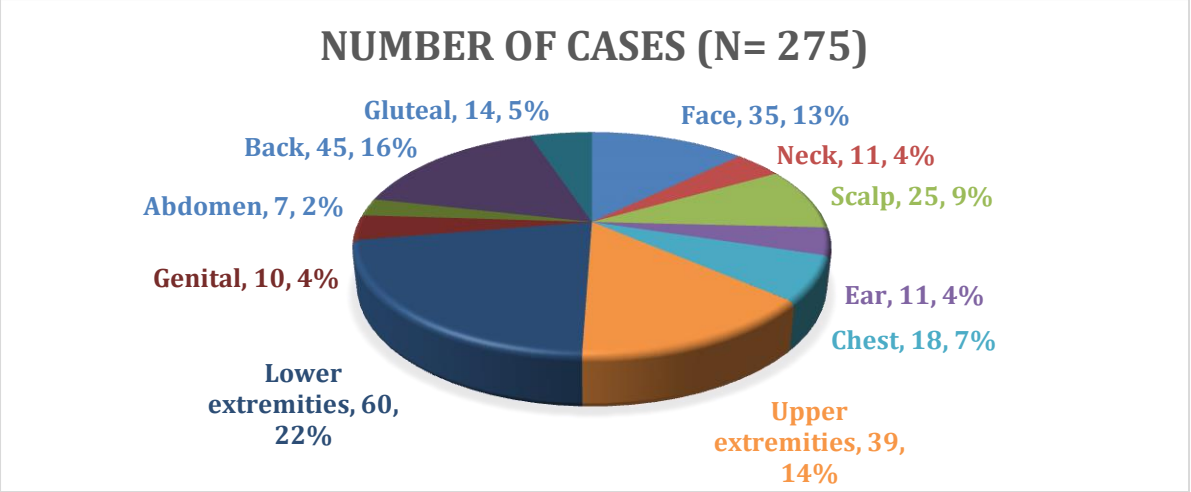

Figure2. Site-wise Distribution of Skin Biopsy Specimens Included in the Study (n = 275)

Table 1. Spectrum of Skin Diseases Based on Histopathological Diagnosis (n = 275)

Histopathological category	Number of cases (n= 275)	Percentage (%)
Cystic lesions	135	49.1
Benign neoplastic lesions	23	8.4
Hyperkeratotic/reactive keratotic lesions	18	6.5
Non-infectious erythematous, papular and squamous/inflammatory diseases	14	5.1
Microbial diseases	27	9.8
Malignant neoplastic lesions	11	4.0
Adnexal neoplasms	9	3.3
Vascular diseases	6	2.2
Other non-neoplastic lesions	4	1.5
Inconclusive	6	2.2
Non-infectious vesicobullous and vesicopustular diseases	6	2.2
Connective tissue/metabolic diseases	3	1.1
Pigmentary disorders	6	2.2
Photosensitivity	1	0.4
Degenerative/perforating disorders	1	0.4
Disorders of superficial cutaneous reactive unit	5	1.8

Table 1A. Distribution of Cystic Lesions According to Histopathological Diagnosis

Histopathological diagnosis	Number of cases (n)
Epidermal cyst	120
Dermoid cyst	8
Pilar cyst	7
Total	135

 © 2026 Arthy Subramanian et al. Open Access under the Creative Commons Attribution 4.0 International License.

Table 1B. Distribution of Benign Neoplastic Lesions According to Histopathological Diagnosis

Histopathological diagnosis	Number of cases (n)
Pyogenic granuloma	14
Xanthomatous dermatofibroma	3
Dermatofibroma	2
Acanthotic seborrhoeic keratosis	1
Verrucous hemangioma	1
Cornu cutaneum	2
Total	23

Table 1C. Distribution of Malignant Neoplastic Lesions According to Histopathological Diagnosis

Histopathological diagnosis	Number of cases (n)
Squamous cell carcinoma (SCC)	2
Basal cell carcinoma (BCC)	5
Verrucous carcinoma	3
Lymphoma cutis	1
Total	11

Table 1D. Distribution of Adnexal Neoplasms According to Histopathological Diagnosis

Histopathological diagnosis	Number of cases (n)
Pilomatricoma	3
Chondroid syringoma	1
Benign adnexal neoplasm	1
Nodular hidradenoma	1
Nevus sebaceous	2
Angiokeratoma	1
Total	9

Table 1E. Distribution of Non-infectious Erythematous, Papular and Squamous/Inflammatory Diseases

Histopathological diagnosis	Number of cases (n)
Psoriasis vulgaris	3
Pustular psoriasis	1
Parapsoriasis	3
Guttate psoriasis	1
Pityriasis lichenoides chronica	1
Discoid lupus erythematosus	1
Keratosis pilaris	1
Lichen planus pigmentosus	1
Lichen planus	1
Hypertrophic lichen planus	1
Total	**14**

Table 1F. Distribution of Microbial Diseases According to Histopathological Diagnosis

Histopathological diagnosis	Number of cases (n)
Bacterial -Leprosy	9
Tuberculoid leprosy	2
Tuberculoid leprosy with Type 1 lepra reaction	1
Borderline tuberculoid leprosy	1
Borderline tuberculoid leprosy downgrading to lepromatous leprosy	1
Borderline lepromatous leprosy	1
Lepromatous leprosy	1
Erythema nodosum leprosum	1
Possibility of early leprosy	1
Bacterial	3
Lupus vulgaris	1
TB granuloma of skin	1
Tuberculosis verrucosa cutis	1

 © 2026 Arthy Subramanian et al. Open Access under the Creative Commons Attribution 4.0 International License.

Viral	6
Verruca vulgaris	2
Infected plantar wart	1
Myrmecia wart	2
Infected verruca plantaris	1
Other microbial	9
Actinomycetoma	1
Furuncle	1
Pilonidal sinus	7
Total	27

Table 1G. Distribution of Vascular Diseases According to Histopathological Diagnosis

Histopathological diagnosis	Number of cases (n)
Leukocytoclastic vasculitis	4
Drug-induced vasculitis	1
Neutrophilic small-vessel vasculitis	1
Total	6

Table 1H. Distribution of Non-infectious Vesicobullous and Vesicopustular Diseases According to Histopathological Diagnosis

Histopathological diagnosis	Number of cases (n)
Pemphigus vulgaris	1
Bullous pemphigoid	3
Bullous impetigo	1
Lichen simplex chronicus	1
Total	6

Table 2. Concordance Between Clinical and Histopathological Diagnoses Among Skin Biopsy Specimens (n = 275)

Concordance category	Number of cases (n)	Percentage (%)
Complete concordance (CC)	207	75.3
Partial concordance (PC)	19	6.9
Discordance (DC)	49	17.8

DISCUSSION

The current retrospective study has identified the histopathological spectrum of 275 skin biopsy specimens from a tertiary care hospital. The study found a varied spectrum of cystic, neoplastic, infectious, inflammatory, vascular, pigmentary, vesicobullous, and adnexal lesions. This kind of variation is typical of dermatopathology, in which lesions that are similar in clinical appearance may actually have very different pathologies.

Cysts formed the biggest category in the current study, comprising 135 cases (49.1%). Among cysts, epidermal cysts were the most commonly observed lesion type (120/135; 88.9%), followed by dermoid cysts and pilar cysts. This is in keeping with clinicopathologic studies conducted on cutaneous cysts in past studies. In a recent Indian study where 324 histologically confirmed cutaneous cysts were studied, epidermal cysts were observed to be the most common type of cyst, forming 89.8% of cases.[10] Also, a study that analyzed more than 9436 biopsies, including 3170 benign tumors, reported epidermal cysts among the most common benign tumors.[11] The significance of histopathology in cystic lesions is the fact that complications such as rupture, inflammation, foreign body reaction, and occasionally malignancy might complicate the seemingly benign process.[12]

Neoplastic benign lesions accounted for 23 lesions (8.4%), with pyogenic granuloma as the most common. Pyogenic granuloma is actually called lobular capillary hemangioma and is a benign blood vessel tumor that can resemble other vascular or malignant lesions.[13] The frequent occurrence of this lesion in skin biopsy specimens highlights the significance of confirmation through histopathology whenever a fast-growing, bleeding, or ulcerated skin lesion is seen. In this study, some other benign lesions were dermatofibroma, xanthomatous dermatofibroma, cornu cutaneum, seborrhoeic keratosis, and verrucous hemangioma. These findings further demonstrate the broad morphological spectrum encountered in routine skin biopsy practice.

 © 2026 Arthy Subramanian et al. Open Access under the Creative Commons Attribution 4.0 International License.

Adnexal neoplasms occurred in 9 patients (3.3%), which included pilomatricoma, nevus sebaceous, chondroid syringoma, and nodular hidradenoma. Adnexal cutaneous tumors are rare, but form a varied group of lesions demonstrating differentiation to follicular, sebaceous, apocrine or eccrine adnexal structures.[14] In a three-year study of 110 cases of adnexal neoplasms, Kaur et al. observed that most cases were benign and showed differentiation toward sweat glands and follicles.[15] Also, a larger series from India, comprising 395 cases of adnexal tumors, showed that about 90% were benign and that histopathological correlation was very important.[16]The presence of several different adnexal tumor types in the current series is consistent with these observations.

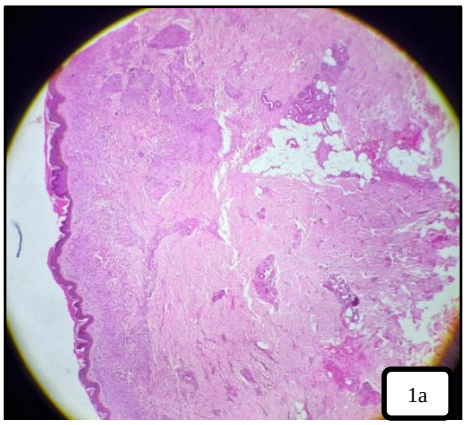

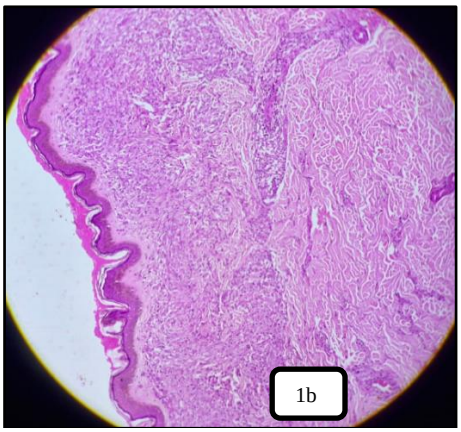

Figure. 1a & 1b H&E (4x) Shows flattened epidermis with grenz zone, and dermis showing granulomas extending into subcutaneous tissue. (10x) shows foamy granulomas composed of foamy macrophages, globi, and plasma Cells.

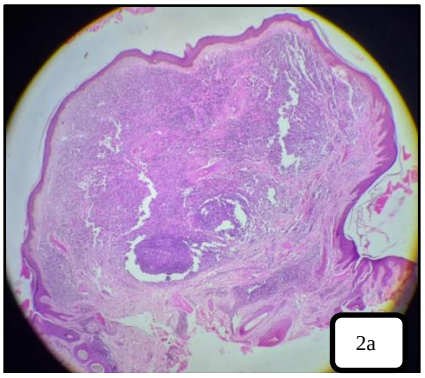

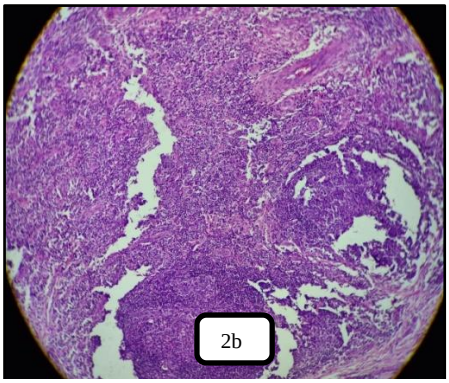

Figure 2a & 2b H&E (4x) lymphocytoma cutis showing lymphoid follicles, nodular and Perivascular Collections of lymphocytes, histiocytes, Plasma cells, and eosinophils. (10x) Showing lymphoid follicles with germinal centers with atypical cells and numerous mitoses.

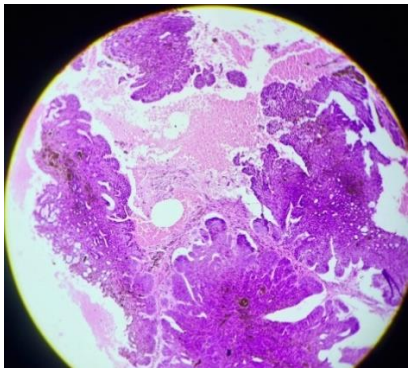

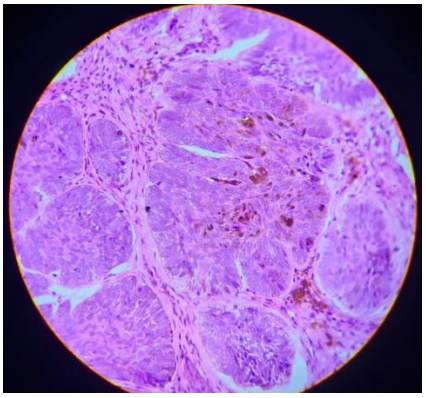

Figure. 3a & 3b H&E (4x) Pigmented BCC Showing Cellular neoplasm arising from the basal layer, composed of solid nests & nodules of cells with Peripheral palisading and retraction artifact. (10x) Showing tumour cells with hyperchromatic nuclei, scant cytoplasm, frequent mitoses, melanin pigment,

 © 2026 Arthy Subramanian et al. Open Access under the Creative Commons Attribution 4.0 International License.

and melanocytes. Figure 2a & 2b H&E (4x) lymphocytoma cutis showing lymphoid follicles, nodular and Perivascular Collections of lymphocytes, histiocytes, Plasma cells, and eosinophils. (10x) Showing lymphoid follicles with germinal centers with atypical cells and numerous mitoses.

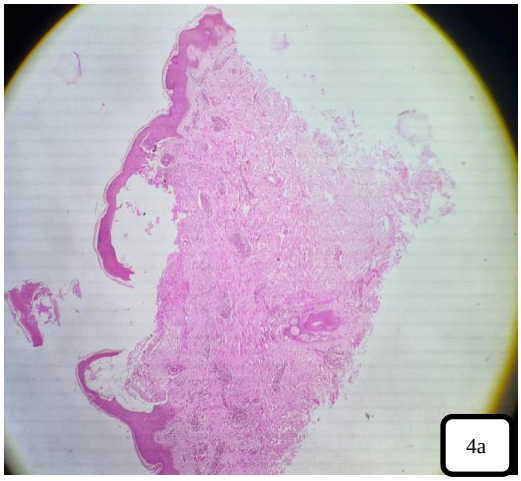

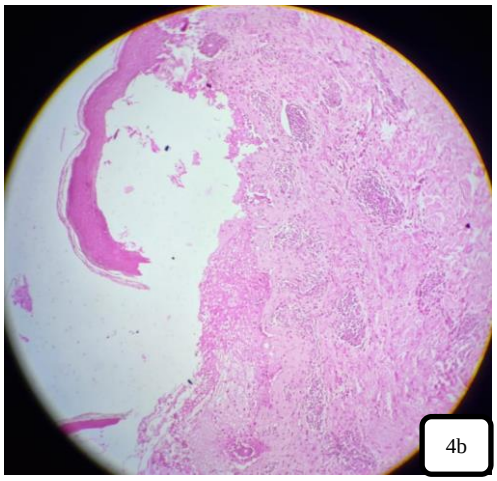

Figure 4a & 4b H&E (4x) Bullous Pemphigoid Showing Subepidermal bullae. (10x) Bullous cavity Showing Proteinaceous Exudate with many Eosinophils and few neutrophils.

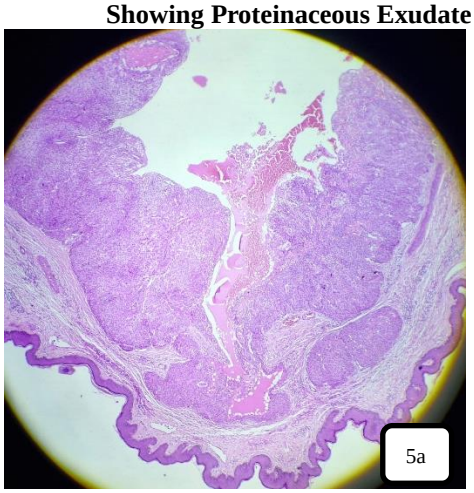

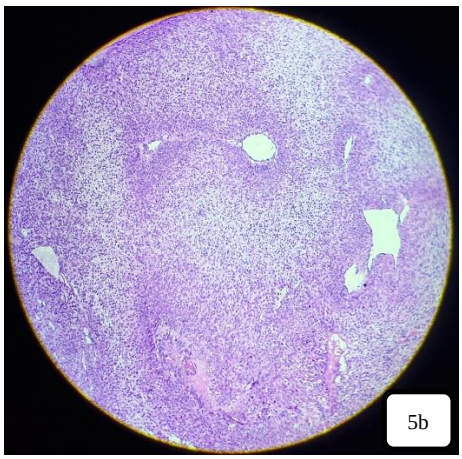

Figure 5a & 5b H&E (4x) Nodular hidradenoma showing a circumscribed dermal neoplasm composed of nodules with 2 cell types and cystic change with hemorrhage. (10X) - Showing nodules composed of a dual population of Cells – polygonal basophilic cells & clear Cells.

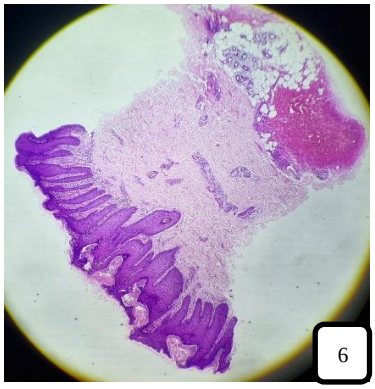

Fig 6: (H & E 4x) Psoriasis Vulgaris with epidermis showing the characteristic elongated rete ridges with bulbous ends.

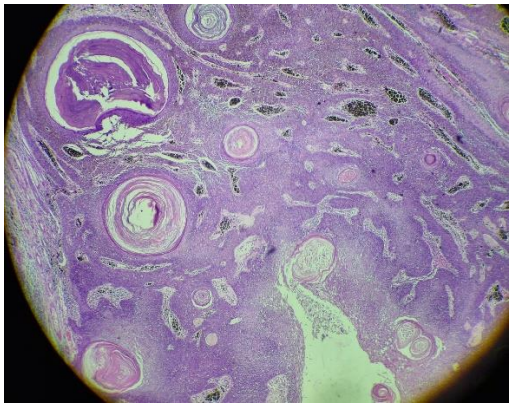
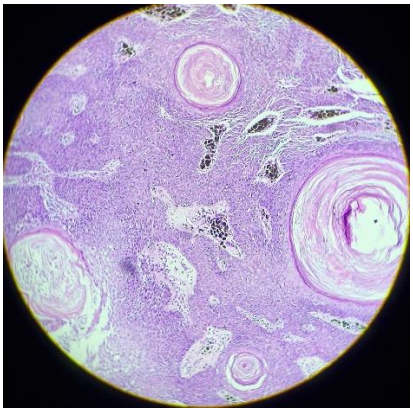

Fig 7a&b (H&E 4x, 10x) Acanthotic seborrheic keratosis Show epidermis with hyperkeratosis, papillomatosis and pseudo horn cysts.

Diseases caused by microorganisms were diagnosed in 27 patients (9.8%), constituting one of the most common groups of diseases for which the diagnosis was made in this study. Leprosy, cutaneous tuberculosis, and viral/other microbial diseases comprised the various categories within this group. The persistence of infectious diseases in the series based on biopsies becomes very important against the backdrop of the Indian situation. As the Global Burden of Disease study has shown, there is a significant global burden of diseases of the skin and subcutaneous tissue, including infectious diseases in particular.[14] A similar Indian burden of the disease study has also highlighted a considerable burden due to both infectious and non-infectious skin diseases.[17] Hospital-based studies from India have also identified infectious diseases as an important component of dermatological morbidity. [18,19]

Leprosy diagnosis was a significant focus of the current study. Histopathology plays a vital role in diagnosing and classifying leprosy, especially when it is not clinically evident or it falls into the borderline spectrum. In a study by Bijjaragi et al. in 171 patients with leprosy, clinical and histopathological features showed overall concordance of 57.3%, with better concordance at both poles of the Ridley-Jopling classification and lower concordance in borderline leprosy.[20] It clearly indicates the diagnostic challenges in diagnosing leprosy and justifies the use of skin biopsy wherever necessary. Histopathological features show characteristic granulomatous patterns and, whenever necessary, acid-fast bacilli on appropriate staining.[21,22] Thus, it reflects the significance of diagnosis of leprosy cases in the current study.

There were 3 patients with cutaneous tuberculosis in our study series. While being rare in comparison to other infectious skin diseases, cutaneous tuberculosis is a disease with wide clinical and morphological variety. Sharma et al. examined 165 Indian patients and found out different clinical variants, such as lupus vulgaris, tuberculosis verrucosa cutis, scrofuloderma and tuberculids.[23] Histological examination was important for diagnosis in a large percentage of patients studied by Sharma et al., which emphasizes the value of examination in cases of suspicion of cutaneous tuberculosis. Indian patients diagnosed more recently also confirmed this point.[23]

The study further revealed 18 hyperkeratotic/reactive keratotic lesions (6.5%) and 13 non-infectious erythematous, papular, squamous and inflammatory conditions (4.7%). These conditions tend to be difficult to diagnose as there is potential overlap between the different inflammatory, reactive, infectious, and malignant disorders based on clinical morphologic appearance. In this regard, histopathology provides crucial information about the nature of skin changes in terms of epidermal and dermal involvement. The range of conditions seen in this study is similar to that seen in earlier histopathologic series where inflammatory, keratotic and papulosquamous conditions were common.[2,3]

Vesicobullous and vesicopustular conditions were seen in 6 patients (2.2%). Despite their low frequency, such lesions are diagnostically important due to the fact that there are a number of blistering conditions which, although being clinically similar, have different histopathological appearances and may require further diagnostic tests like direct immunofluorescence. Current clinicopathological reports have shown varying degrees of agreement among vesiculobullous lesions, highlighting the need for using a combination of clinical and histopathological approaches in diagnosing such lesions.[24] The small number of such lesions observed in this study is likely to be due to the selection criteria for biopsy submissions.

There were 6 cases (2.2%) of vascular lesions, in which the most common type was leukocytoclastic vasculitis. Histological evaluation is especially significant in cases of suspected cutaneous vasculitis since the diagnosis depends on identification of characteristic changes in the walls of blood vessels and the type of inflammatory cells that make up the infiltrate. It is especially important to have an adequate biopsy technique that involves selecting a right aged and sized sample from the lesion.[25]

Pigmentary disorders made up 6 cases (2.2%), whereas other types of disorders, such as superficial cutaneous reactive unit lesions, connective tissue/metabolic disorders, other non-neoplastic lesions, cutaneous toxicity and degenerative/perforating lesions, were found less often. Low frequency of these categories of disorders should be evaluated bearing in mind that this is a hospital-based study and not a prevalence estimate. Common disorders in the community can rarely be subjected to biopsy, whereas clinically uncertain, unusual or refractory lesions are usually biopsied.

There were 11 cases (4.0%) with malignant neoplastic lesions in our study. The commonest malignancy observed was basal cell carcinoma, followed by verrucous carcinoma and squamous cell carcinoma, with cutaneous lymphoma as one case. Skin malignancies are relatively uncommon when compared with cancers in Western countries; however, they form a significant clinical entity since the early lesions might mimic other benign or inflammatory skin diseases.[26,27] In a retrospective study conducted in India on cutaneous malignancies, BCC was the commonest malignancy, followed by SCC and melanoma, with predilection for the head and neck.[27] In another study from India in a tertiary care hospital on 230 cases of primary skin malignancies, SCC was the commonest histological type of skin malignancy, followed by BCC and melanoma.[26]

The limited occurrence of malignant lesions in this study should not be taken to mean that there is a low population incidence of cancer since the study involved only those specimens which were subjected to histopathological studies. However, the presence of malignant tumors in the biopsy specimens underscores the significance of histopathological studies of clinically suspicious lesions. There have been variations in the relative occurrence of BCC and SCC recorded in studies from India. For instance, Khullar et al. found 170 cases of BCC and 82 cases of SCC among more than 13,000 skin biopsies.[28]

The clinicopathological agreement was one of the significant outcomes of the current study. A complete agreement was noted in 207 cases (75.3%), partial agreement in 19 cases (6.9%), and a disagreement in 49 cases (17.8%). Hence, there was an 82.2% agreement between the clinicopathological aspects. The results obtained from the current study have been found to be similar to those in the published literature; however, caution needs to be exercised while comparing numbers owing to the variation in definitions for complete, partial, and overall concordance between different studies. Aslan et al. observed 76.8% concordance in their study on 3949 skin biopsies.[29] Balasubramanian et al. found a complete concordance in 59.8% and partial concordance in 7.6% out of 3006 biopsies from a tertiary care center in India.[30] Malik et al. reported 61.01% concordance out of 2216 Indian skin biopsies, while 31.54% were reported with descriptive pathological diagnosis, which did not correspond with the clinical diagnosis.[31] In contrast, a recently conducted study on 5000 skin biopsies found an overall concordance of 86%, including 50.6% complete and 35.4% partial concordance.[32] In a 2025 study in India on 321 skin biopsies, clinicopathological concordance was reported as 72.6%.[33]

SUMMARY

In the current research, the histopathological characteristics of the neoplastic and non-neoplastic skin lesions observed at a tertiary care hospital have been assessed. A retrospective observational study was conducted on patients with skin biopsies and skin excision specimens, with collection and analysis of pertinent demographic, anatomical, clinical, and histopathological data. The majority of cases were non-neoplastic lesions, with cystic lesions being the commonest type, followed by benign neoplastic, reactive, inflammatory, infectious, and other non-neoplastic lesions, while malignant neoplasms were less common but still of clinical significance. These results show that there is a broad range of cutaneous lesions in routine clinical practice, and that histopathology plays a critical role in diagnosis and differentiation.

Acknowledgment: The authors sincerely acknowledge the support and cooperation of the Department of Pathology, Sri Muthukumaran Medical College and Research Institute (SMMCH), Chennai, Tamil Nadu, India, and all faculty, technical staff, and colleagues who contributed to this study.

Conflict of interest:

Funding: Nil

REFERENCE

1. Agarwal S, Krishnamurthy K. Histology, Skin. In: StatPearls [Internet]. Treasure Island (FL):

 © 2026 Arthy Subramanian et al. Open Access under the Creative Commons Attribution 4.0 International License.

StatPearls Publishing; 2026 [cited 2026 Sep 6]. Available from: http://www.ncbi.nlm.nih.gov/books/NBK537325/ PubMed PMID: 30726010.
2. Dawande P, Wankhade R, Sajjanar AB, Bankar NJ. A Histopathological Study of the Spectrum of Skin Lesions in a Tertiary Care Hospital: A Retrospective Study. Cureus. 15(10):e47164. doi:10.7759/cureus.47164 PubMed PMID: 38021851; PubMed Central PMCID: PMC10652029.
3. Dimri D, Reddy B V, Kumar Singh A. Profile of Skin Disorders in Unreached Hilly Areas of North India. Dermatol Res Pract. 2016;2016:8608534. doi:10.1155/2016/8608534 PubMed PMID: 27738425; PubMed Central PMCID: PMC5050382.
4. Kavita K, Mehta H, Ghai S, Saini SK, Narang T. Self-reported prevalence of skin problems among residents of a peri-urban community of Chandigarh. **Indian J Dermatol Venereol Leprol.** 2024;90(4):565. doi:10.25259/IJDVL_982_2022. PMID: 37609756.
5. Talwar A, Ballambat SP, Rao R, Shetty VM. Clinico-Pathological Correlation in Dermatological Disorders: A Retrospective Audit of 332 Skin Biopsies from a Tertiary Care Center. Indian Dermatol Online J. 2022 Dec 14;14(1):61–6. doi:10.4103/idoj.idoj_241_22 PubMed PMID: 36776159; PubMed Central PMCID: PMC9910537.
6. George VP, Sowmya S, Krishnan S. A histopathological study of skin biopsy specimens in a tertiary care hospital with a keynote on clinicopathological correlation. **Ann Pathol Lab Med.** 2020;7(1):A39-A45. doi:10.21276/APALM.2670.
7. Alguire PC, Mathes BM. Skin Biopsy Techniques for the Internist. J Gen Intern Med. 1998 Jan;13(1):46–54. doi:10.1046/j.1525-1497.1998.00009.x PubMed PMID: 9462495; PubMed Central PMCID: PMC1496896.
8. Ramsey ML, Conrad E, Chen RL, Rostami S. Skin Biopsy. In: StatPearls [Internet]. Treasure Island (FL): StatPearls Publishing; 2026 [cited 2026 Sep 6]. Available from: http://www.ncbi.nlm.nih.gov/books/NBK470457/ PubMed PMID: 29262109.
9. Patel T, Singh G, Bhankhodia V, Rachani K, Dangar A, Berani J, et al. Retrospective study of histomorphological examination of skin lesion biopsies and their clinical concordance: experience from a tertiary care hospital in India. J Med Life. 2025 Nov;18(11):1016–23. doi:10.25122/jml-2025-0114 PubMed PMID: 41532048; PubMed Central PMCID: PMC12794105.
10. Khullar G, Chandra M. Clinicopathological Appraisal of Cutaneous Cysts: A 2-Year Retrospective Observational Study. Indian Dermatol Online J. 2023 Oct 27;14(6):844–8. doi:10.4103/idoj.idoj_239_23 PubMed PMID: 38099050; PubMed Central PMCID: PMC10718123.
11. Káram-Orantes M, Fonte-Avalos V, Zuloaga-Salcedo S, Domínguez-Cherit J. [Frequency of benign tumors at the Hospital General "Dr. Manuel Gea Gonzalez". Record review between 2000-2006]. Gac Med Mex. 2007;143(5):371–5. PubMed PMID: 18246930.
12. Jenkins MA, Morgan MB. Dermal cysts: a dermatopathological perspective and histological reappraisal. **J Cutan Pathol.** 2007;34(9):646-653. doi:10.1111/j.1600-0560.2007.00746.x.
13. Bejjanki KM, Mishra DK, Kaliki S. Periocular lobular capillary hemangioma in adults: a clinicopathological study. **Middle East Afr J Ophthalmol.** 2019;26(3):138-140. doi:10.4103/meajo.MEAJO_42_19.
14. Kavita A, Thakur JS, Narang T. The burden of skin diseases in India: Global Burden of Disease Study 2017. Indian J Dermatol Venereol Leprol. 2023;89(3):421–5. doi:10.25259/IJDVL_978_20. PubMed PMID: 34877854.
15. Kaur K, Gupta K, Hemrajani D, Yadav A, Mangal K. Histopathological Analysis of Skin Adnexal Tumors: A Three-Year Study of 110 Cases at A Tertiary Care Center. Indian J Dermatol. 2017;62(4):400–6. doi:10.4103/ijd.IJD_380_16. PubMed PMID: 28794552; PubMed Central PMCID: PMC5527722.
16. Sharma N, Nakra T, Agarwal S, Gupta V, Singh MK, Arava S. Cutaneous Adnexal Tumours: A Study of 395 Cases from a Tertiary Care Hospital. Indian J Dermatol. 2023;68(1):41–4. doi:10.4103/ijd.ijd_586_22 PubMed PMID: 37151257; PubMed Central PMCID: PMC10162737.
17. Kavita A, Thakur JS, Narang T. The burden of skin diseases in India: Global Burden of Disease Study 2017. Indian J Dermatol Venereol Leprol. 2023;89(3):421–5. doi:10.25259/IJDVL_978_20 PubMed PMID: 34877854.
18. Kar C, Das S, Roy AK. Pattern of skin diseases in a tertiary institution in kolkata. Indian J Dermatol. 2014 Mar;59(2):209. doi:10.4103/0019-5154.127707 PubMed PMID: 24700954; PubMed Central PMCID: PMC3969696.
19. Grover S, Agale SV, D'Costa GF, Valand AG, Gupta VK. Clinico-Histopathological Spectrum of Infectious Granulomatous Dermatoses in Western India- A Representative Study from Mumbai. J Clin Diagn Res. 2016 Apr;10(4):EC10-14. doi:10.7860/JCDR/2016/16459.7568 PubMed PMID: 27190811; PubMed Central PMCID: PMC4866109.
20. Bijjaragi S, Kulkarni V, Suresh KK, Chatura KR, Kumar P. Correlation of clinical and histopathological classification of leprosy in post elimination era. Indian J Lepr. 2012;84(4):271–5. PubMed PMID: 23720892.

 © 2026 Arthy Subramanian et al. Open Access under the Creative Commons Attribution 4.0 International License.

21. Giridhar M, Arora G, Lajpal K, Singh Chahal K. Clinicohistopathological concordance in leprosy - a clinical, histopathological and bacteriological study of 100 cases. Indian J Lepr. 2012;84(3):217–25. PubMed PMID: 23484336.
22. Joshi R. Clues to histopathological diagnosis of treated leprosy. Indian J Dermatol. 2011;56(5):505–9. doi:10.4103/0019-5154.87132 PubMed PMID: 22121264; PubMed Central PMCID: PMC3221209.
23. Sharma S, Sehgal VN, Bhattacharya SN, Mahajan G, Gupta R. Clinicopathologic spectrum of cutaneous tuberculosis: a retrospective analysis of 165 Indians. Am J Dermatopathol. 2015 Jun;37(6):444–50. doi:10.1097/DAD.0000000000000297 PubMed PMID: 25839888.
24. Daniel S, Nandakumar G, Krishna G, Balachandran N, Sadasivan S. Clinicopathological study of vesiculobullous diseases with special emphasis on autoimmune disorders: a two-year study in a resource setting. **Int J Med Res Health Sci.** 2020;9(12):14-32.
25. Khetan P, Sethuraman G, Khaitan BK, Sharma VK, Gupta R, Dinda AK, et al. An aetiological & clinicopathological study on cutaneous vasculitis. Indian J Med Res. 2012 Jan;135(1):107–13. doi:10.4103/0971-5916.93432 PubMed PMID: 22382191; PubMed Central PMCID: PMC3307169.
26. Sharma P, Aggarwal P, Punia RS, Bhagat R, Handa U, Sandhu JK. Clinico-pathological Spectrum of Primary Skin Malignancies in an Indian Tertiary Care Hospital. Indian J Dermatol. 2023;68(6):723. doi:10.4103/ijd.ijd_401_23 PubMed PMID: 38371551; PubMed Central PMCID: PMC10869018.
27. Supekar BB, Tomar SS, Wankhade VH, Bhushan R, Singh RP, Bhat DM. Clinical Spectrum of Cutaneous Malignancies in Central India: A Retrospective Study. Indian J Dermatol. 2021;66(3):284–90. doi:10.4103/ijd.IJD_543_19 PubMed PMID: 34446952; PubMed Central PMCID: PMC8375545.
28. Khullar G, Saikia UN, De D, Handa S, Das Radotra B. Predisposing factors and histopathological variants of cutaneous squamous cell carcinoma: Experience from a North Indian teaching hospital. Indian J Dermatol Venereol Leprol. 2016;82(3):273–8. doi:10.4103/0378-6323.168936 PubMed PMID: 27088928.
29. Aslan C, Göktay F, Mansur AT, Aydıngöz IE, Güneş P, Ekmekçi TR. Clinicopathological consistency in skin disorders: a retrospective study of 3949 pathological reports. J Am Acad Dermatol. 2012 Mar;66(3):393–400. doi:10.1016/j.jaad.2010.12.031 PubMed PMID: 22142653.
30. Balasubramanian P, Chandrashekar L, Thappa DM, Jaisankar TJ, Malathi M, Ganesh RN, et al. A retrospective audit of skin biopsies done in a tertiary care center in India. **Int J Dermatol.** 2015;54(8):939-943. doi:10.1111/ijd.12718.
31. 3Malik A, Siraj F, Shruti S, Gupta P, Khullar G, Ramesh V. Clinicopathological Concordance in 2216 Cases of Skin Biopsy over One Year: An Indian Experience. Cureus. 2020 Apr 20;12(4):e7752. doi:10.7759/cureus.7752 PubMed PMID: 32455069; PubMed Central PMCID: PMC7243079.
32. Singh S, Thirumalaiswamy A, Kharkar V, Mahajan S, Joshi R, Sharath SM. From clinic to microscope: A study of clinicopathological concordance in 5000 skin biopsies from a tertiary care center. J Postgrad Med. 2026 Apr 1;72(2):56–62. doi:10.4103/jpgm.jpgm_613_25 PubMed PMID: 42301682; PubMed Central PMCID: PMC13390951.
33. Patel T, Singh G, Bhankhodia V, Rachani K, Dangar A, Berani J, et al. Retrospective study of histomorphological examination of skin lesion biopsies and their clinical concordance: experience from a tertiary care hospital in India. J Med Life. 2025 Nov;18(11):1016–23. doi:10.25122/jml-2025-0114 PubMed PMID: 41532048; PubMed Central PMCID: PMC12794105.

 © 2026 Arthy Subramanian et al. Open Access under the Creative Commons Attribution 4.0 International License.